

ORIGINAL COMMUNICATION

Investigation of the Functional Three-Dimensional Anatomy of the Human Cystic Duct: A Single Helix?

N.C. BIRD,^{1*} R.C. OOI,² X.Y. LUO,^{2†} S.B. CHIN,² AND A.G. JOHNSON³

¹Liver Research Group, University of Sheffield, Sheffield, United Kingdom

²Department of Mechanical Engineering, University of Sheffield, Sheffield, United Kingdom

³Emeritus Professor of Surgery, University of Sheffield, Sheffield, United Kingdom

Clinical research into the formation of gallstones has indicated that the anatomy of the cystic duct is one of a number of factors contributing to the formation of gallstones. The cystic duct allows low-viscosity hepatic bile to enter the gallbladder under low pressure and the expulsion of a more viscous gallbladder bile, but little is known about this transport mechanism and the effect of anatomical variations in structure. This article describes the variation in geometry of the cystic duct, obtained from acrylic resin casts of the neck and first part of the cystic duct in gallbladders removed for gallstone disease and obtained from patients undergoing partial hepatectomy for metastatic disease. The data obtained allowed us to formulate a number of standard terms for describing cystic duct morphology and demonstrate that the term “spiral valve” is only partially correct when describing the duct anatomy. In over half of the casts, spiraling was not the dominant feature of the cystic duct. Additionally, the term valve implies active resistance to flow in one direction, whereas the internal baffles of the cystic duct would serve to regulate bile flow in both directions. These data are useful for realistic 3D modeling of fluid-structure interactions of the flow of bile in the human cystic duct. *Clin. Anat.* 19:528–534, 2006. © 2005 Wiley-Liss, Inc.

Key words: gallbladder; valves of Heister; computational fluid dynamics

INTRODUCTION

Gallbladder stasis and incomplete emptying are known risk factors for the formation of gallstones. Since the ability of the gallbladder to expel bile is usually only compromised in those patients with a gallbladder wall thickened by scar tissue, the majority of patients undergoing surgery for gallstone disease have no intrinsic, primary abnormality of gallbladder muscle (Wegstapel et al., 1999; Ahmed et al., 2000; Bird et al., 2002). Thus, other factors are likely to contribute to the formation of gallstones.

The human cystic duct functions as a single conduit for the transport of bile during both filling and emptying of the gallbladder. Anatomical descriptions of the duct date back to the middle of the 18th century when Heister (1732) reported his observation of spiraling folds in the lumen of the duct and described them as valves. Although their valvular function has never been properly established, the term “valves of Heister” is still commonly used. Anatomically, the gallbladder neck narrows and develops mucosal folds

before funneling into the duct. “Spiraling” mucosal folds are generally prominent in the proximal duct (also known as the pars spiralis or pars convoluta), but these folds then flatten out to form a circular lumen at the distal end (pars glabra).

A number of investigations have studied the physiological function of the cystic duct (Otto et al., 1979; Scott and Otto, 1979; Pitt et al., 1981). Although it was discovered that duct resistance was a significant factor affecting flow within the biliary system, these studies offered no description of flow

*Correspondence to: Dr. N.C. Bird, Liver Research Group, K Floor, Royal Hallamshire Hospital, Glossop Road, Sheffield S10 2JF, UK. E-mail: n.bird@shef.ac.uk

†X.Y. Luo’s present address is Department of Mathematics, University of Glasgow, Glasgow, UK.

Received 3 February 2005; Revised 19 April 2005; Accepted 14 June 2005

Published online 14 November 2005 in Wiley InterScience (www.interscience.wiley.com). DOI 10.1002/ca.20219

within the duct and no firm conclusions regarding the true purpose of the valves of Heister. Human cystic duct anatomy has been described mostly from dissection of the duct at postmortem, where the surfactant properties of bile may have altered the anatomy. Gray and Lewis (1918) reported that the mucosal folds project into the lumen in the form of oblique ridges or crescentic folds, presenting the appearance of a continuous spiral valve. Similar crescent-shaped valves have also been reported in the porcine cystic duct by Steiner et al. (1989). Mentzer (1926) had observed what he called "leaflets" in the lumen of the duct after incising it longitudinally. He went on to describe instances where several "leaflets" joined to form spiral "valves," a description also used by Lichtenstein and Ivy (1937). Sketches from their observations showed longitudinal sections of the human cystic duct containing spiral compartments. Some of these features were so prominent that the exterior of the duct also showed spiral characteristics, which is consistent with the twisted exterior appearance reported by Gray and Lewis (1918).

In computer modeling studies, we have shown that the geometry and morphology of the cystic duct affects the rate of flow as well as the pressure required to initiate and maintain this flow (Luo et al., unpublished communication). Conventional imaging techniques, such as X-ray and magnetic resonance imaging (MRI), give only 2D images with insufficient resolution to identify the finer anatomical structures within the duct (Fig. 1). Similarly, 3D reconstructions of CT or MRI images of the biliary tract only provide a resolution of a few millimeters (Ichii et al., 2002; Ianora et al., 2003). Our initial idealized modeling studies showed that clearance between the baffles within the duct was the most significant factor affecting flow. This study describes the morphology and geometry of resin casts made from the human cystic duct. This will then allow construction of realistic computer models to simulate the flow of bile within the duct. If the baffles within the cystic duct function as a spiral valve, the nature of the flow of bile within the duct will be different to that which would occur if they were simple obstructions to the free flow of bile. This would also have profound implications on the flow of bile with different levels of viscosity, such as low-viscosity hepatic bile and the higher viscosity gallbladder bile (Ooi et al., 2004).

MATERIALS AND METHODS

Casting

The tissue samples used for the casting process were collected from patients undergoing routine chole-

cystectomy ($n = 29$) or liver surgery ($n = 8$). Since this tissue was removed during the course of routine treatment and used solely for the purpose of research, it was covered by the standard hospital consent for operation form and therefore local research ethics committee approval was not required. The gallbladder was collected immediately on removal, placed in cold Krebs solution, and transported to the laboratory within 30 min. The gallbladder was then divided into two by making a transverse incision thus releasing bile, gallstones, and any sediment present. The upper segment, containing the neck and cystic duct, was rinsed and flushed with Krebs solution and mounted in a laboratory clamp so that the distal end of the cystic duct was facing downwards and the neck held open by four clamps mounted at 90° to each other.

A two-part acrylamide resin, mixed according to the manufacturer's instructions (Scott Bader, Strand, UK), was used for making the casts. Following addition of the catalyst, the mixture was introduced slowly into the gallbladder neck, using a 5-ml syringe. To minimize the risk of including trapped air bubbles, water, and other fragments in the cast, resin was allowed to flow freely from the open end of the cystic duct until it set, fresh resin being added to the open neck to maintain a constant level of resin. After leaving overnight to allow complete hardening, the sample tissue was dissected from the finished cast.

The length, minimum and maximum diameters of the resin casts were measured visually to the nearest 0.5 mm, using a ruler. Each diameter recorded was the average of two readings taken at right angles to each other to allow for the fact that the cross section may not have been perfectly round.

3D Scanning

The scanning procedure was done using the Model Maker W (3D Scanners, UK), in which a laser line is projected on to the object. The line is viewed at an angle by cameras and thus height variation in the object is seen by changes in shape of the line.

Sampling at 23,000 points/sec with a sampling pitch of 0.1 mm gave sufficient resolution to construct a realistic electronic 3D model for export into the GAMBIT (Fluent Inc., Sheffield, UK) software, for running computational fluid dynamics (CFD) analysis, and calculations of the geometry such as the internal diameter of the cystic duct (Fig. 2).

Geometry Definition

When translated into a computer reconstruction, the lumen described a course with combinations of complex geometry rather than a passage containing

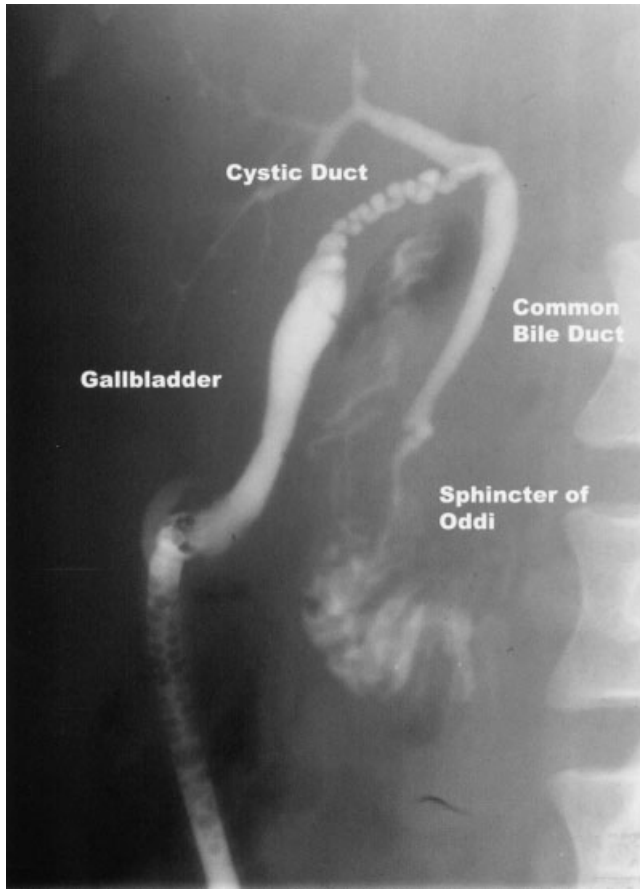


Fig. 1. Operative cholangiogram showing a collapsed gallbladder, an elongated cystic duct, common hepatic duct, common bile duct, and sphincter of Oddi. (Reprinted from Ooi et al. (2004) with kind permission from Elsevier.)

simple crescent shaped folds or “leaflets” as suggested by previous reports. Therefore, a set of geometric terms was used to (a) delineate the various structures, and (b) allow a comparison of the 3D space with previous reports.

Lumen diameter. Maximum and minimum dimensions of the lumen were measured. In cholangiography, the cystic duct diameter is usually taken as the dimension of the whole inner duct that is delineated by X-ray. In this article, the term lumen diameter is used to describe the internal diameter or clearance between the folds within the lumen of the cystic duct.

The length of the cast was divided into three sections namely gallbladder neck, pars spiralis (proximal duct), and pars glabra (distal duct).

Gallbladder neck. From the beginning of any furrows or folds observed on the mucosal surface of the body to the point where the neck narrows markedly to become the cystic duct.

Pars spiralis (proximal duct). Where the diameter of the gallbladder neck narrows to form a tube with complex folding and internal baffles. Loss of such geometry marks the end of the pars spiralis.

Pars glabra (distal duct). This was not examined in detail owing to the variable nature of the dissection by the operating surgeon—it could not be stated with certainty how much of this part of the duct was removed.

Finally, although it is acknowledged that the native angles were unlikely to have been preserved, we measured the angles between the cystic duct and the gallbladder body. These were described as cystic and neck angles, with 0° being defined as continuous with the axis of the gallbladder and 180° when a complete U-turn was described by the cast. The cystic angle is the angle that the cystic duct makes with the central axis of the gallbladder body. The neck angle is the angle between the gallbladder neck and the first part of the cystic duct after the initial bend (Fig. 3).

RESULTS

A total of 37 casts of the superior part of the body, neck, and cystic duct were obtained. In 29 of these, the length of cystic duct cast was sufficient to allow a morphological description and measurements to be made. Figure 4 shows a schematic representation of the features of the casts. Winding was the term used to describe a sinusoidal course with no apparent rotational component.

The “spiral valves” originate in the gallbladder neck and look like small indentations on the funneling neck (Fig. 4e). Some of these furrows form crescentic folds around the neck, others join together, spiral around the neck, and become deeper when approaching the proximal part of the cystic duct. In the proximal part of the duct, the course of the duct undergoes a series of changes in direction that are variously described as spiraling (Fig. 4a) or winding (Fig. 4b). Spiraling with an M-shaped loop was associated with a change in rotational direction (Fig. 4c), whereas winding was associated with kinks (Fig. 4d).

Qualitative Observations

As the neck narrowed towards the duct, the spiral prominences gradually transformed into a helical conduit. When classifying the direction of the spirals (clockwise or counter clockwise), the convention applied in this article is by viewing the cast from the proximal end to the distal part of the duct. The casts were classified according to the first feature observed

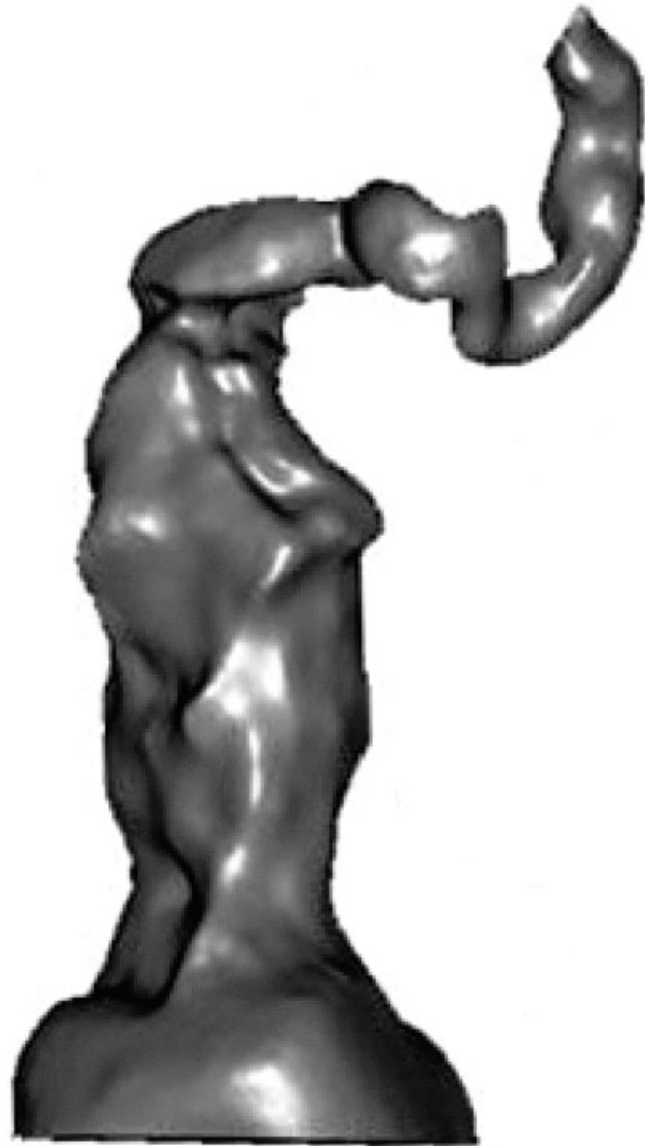

Fig. 2. Acrylic cast of a gallbladder neck and cystic duct on the left and a 3D reconstruction following scanning.

in the pars spiralis, irrespective of whether it changed to a different geometry further down. Figure 5a shows a neck and proximal portion of the cystic duct, demonstrating the increased prominence and organization of the mucosal folds. Figures 5b and 5c show examples of casts with the folds and kinks described earlier. The black spot in Figure 5c is a small gallstone lodged within the duct. Following this, a kink is seen and the duct immediately appears to change in its direction of spiral.

Of the 29 usable casts, nine had a spiral course as the sole feature and 12 had only a winding course. Seven casts had an initial spiral rotation, followed by

a winding course and one cast had a series of continuous kinks. Thirteen of the 16 casts showing at least one initial spiral rotation did so in a clockwise manner and four of these changed rotation to counter clockwise following an M-shaped loop.

Quantitative Measurements

Table 1 shows the quantitative measurements made from the 37 casts in an attempt to define the geometry for subsequent 3D modeling and also to determine whether differences exist between patients with gallstones and those with an apparently

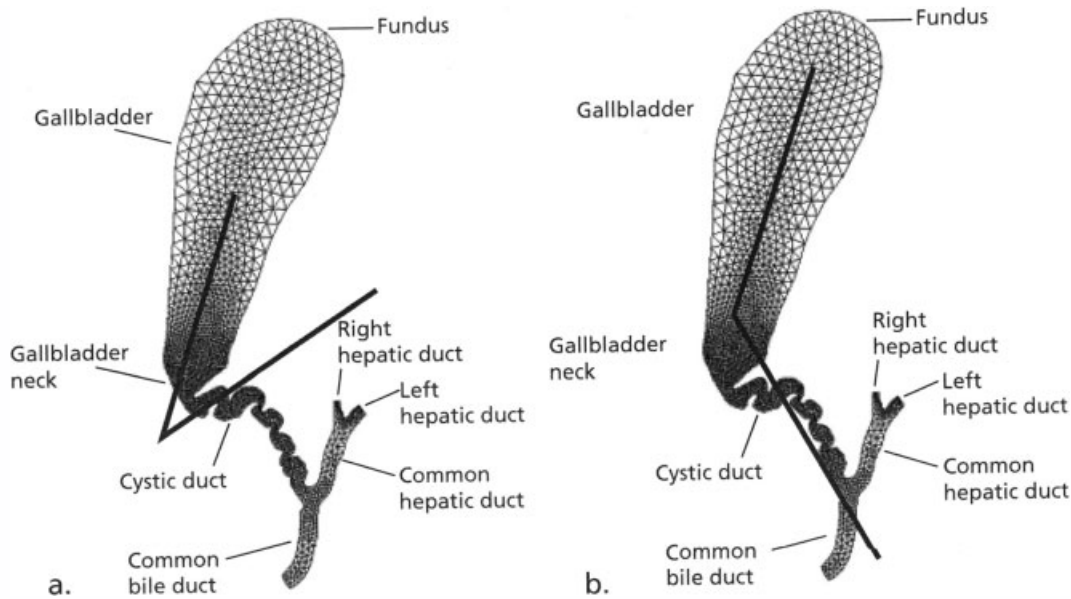


Fig. 3. Angles described by (a) the neck, relative to the central axis of the gallbladder body, and (b) the main part of the cystic duct, relative to the central axis of the gallbladder.

normal gallbladder. In eight cases, there was insufficient casting of the pars spiralis to make measurements meaningful.

Dividing the casts into groups of those obtained from patients with gallstones and those from partial hepatectomies showed a complete overlap in the ranges for all measurements with no significant differences (Kruskal-Wallis analysis of variance). The proportion of patients having angles of 0° in the liver resection group was greater than that of the cholecystectomy group, but this difference was also not statistically significant (Fisher's exact test).

DISCUSSION

There is growing evidence from endoscopic retrograde cholangiography that characteristics of the cystic duct anatomy relate to gallstone disease. Castelain et al. (1993) found that increasing diameter of the duct correlated with increasing severity of gallstone disease, possibly as a result of migration of small stones from the gallbladder causing distension in the duct. Patients without stones had the smallest diameter ducts, followed by those with stones only in the gallbladder. Those with stones in the common bile duct had the greatest diameter. Caroli-Bosc et al. (1997) demonstrated that the site at which the duct joined the common bile duct was more significant than the length of duct, from the point of view of lithogenesis. However, Deenitchin et al. (1998)

reported that patients with cholelithiasis had cystic ducts that were longer, narrower and contained more anomalies in their anatomy than those of a control group of patients without stones.

These resin casts have provided data on the dimensions and geometry of the cystic duct in humans. Despite unequal sizes of the groups, there appear to be no significant differences in length, minimum and maximum diameter, or cystic duct angles between casts obtained from people undergoing cholecystectomy for gallbladder stone disease and those having liver surgery in whom there was no evidence or history of gallbladder disease. The data suggest that the geometry of the cystic duct and gallbladder neck per se are not factors in the development of gallstones. The effects of variation in cystic duct geometry on bile flow are unknown and are the subject of further work by our group.

There has been extensive debate and speculation on the purpose of the valves of Heister. Keith (1903) first proposed that the spiral structure prevented collapse of the duct, whereas Lichtenstein and Ivy (1937) adopted a phylogenic perspective, suggesting that the internal structure of the cystic duct evolved to accommodate its presence in a restricted abdominal compartment. In our study, however, a spiral internal geometry was the sole feature in only nine of the 29 casts evaluated. So, the description of "spiral valves" is only partially correct and certainly not the defining feature of the cystic duct.

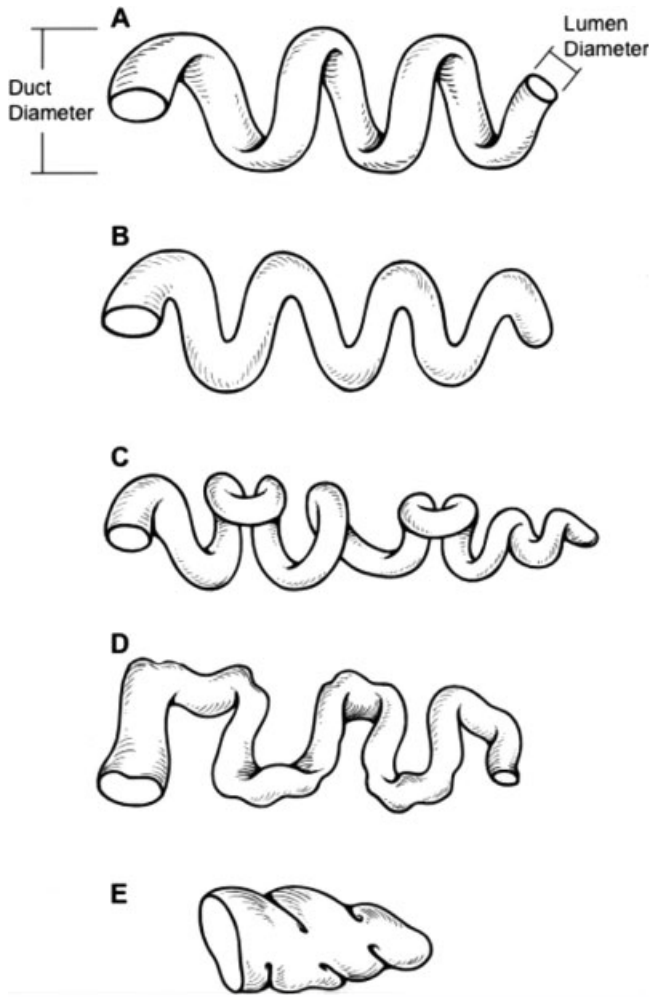


Fig. 4. Artist's schematic representations of the geometries seen in the casts (a) spiral, (b) winding, (c) spiral incorporating and M-shaped loop, (d) folds or kinks, and (e) elliptical furrows in the cast of a gallbladder neck.

Despite originally being viewed as passive flow resistors, the smooth muscle fibres in the duct wall (Jacobson and Gydesen, 1922) have been viewed more recently as part of an active mechanism. Following the observation (Torsoli et al., 1970) that the flow of X-ray contrast medium stopped in the cystic duct, Courtney et al. (1983) found that cholecystokinin also constricted the canine cystic duct. Similar findings led Dodds et al. (1989) to speculate that the valves prevent over distension of the common bile duct during gallbladder contraction by resisting flow. The description of the folds within the lumen as valves implies that they open and close, preventing flow or reflux of bile in one direction. A more accurate term would be baffle-plates, which describes their function more accurately in regulating the inward or outward flow of liquid in the cystic duct.

Biomechanical study of the biliary tract has provided new insights into the nature of bile flow. This approach, using computational fluid dynamics techniques, has led to more complex modeling procedures that include fluid-structure interaction models (Ooi

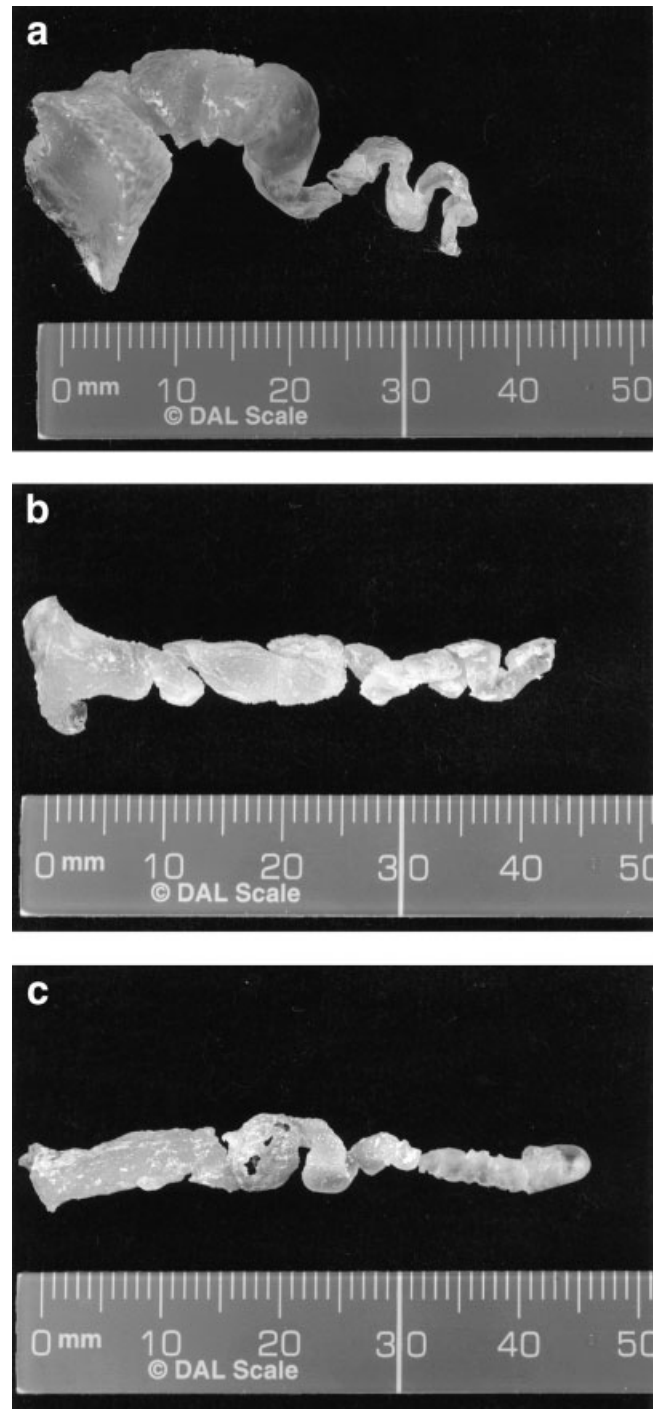


Fig. 5. Examples of acrylic casts (a) neck and tortuous proximal cystic duct, (b) M-shaped loop followed by spiral course, and (c) elongated cystic duct containing a small pigment stone.

TABLE 1. Dimensions of the Resin Casts

	Mean \pm SD	Median	Range	
			Min.	Max.
GB neck ($n = 37$)				
Length (mm)	9.4 \pm 5.3		1.5	22.0
Min. diameter	5.8 \pm 2.0		2.5	11.0
Max. diameter	7.2 \pm 2.1		3.5	12.0
Pars spirals ($n = 29$)				
Length (mm)	9.2 \pm 5.0		2.5	22.0
Min. diameter	1.8 \pm 0.7		0.5	3.0
Max. diameter	2.9 \pm 0.8		1.5	4.5
Cystic duct angles ($^{\circ}$) ($n = 37$)				
Cystic		90	0	165
Neck		25	0	180

et al., 2004). To refine these models, the present work was carried out to provide a more accurate description of the 3D geometry of the gallbladder neck and cystic duct to allow us to construct 3D computer models. These will be used to determine the effect of different cystic duct configurations on bile flow and the pressures required to initiate and maintain flow.

In conclusion, this work has confirmed that the human cystic duct has a mixture of geometric configurations, with features common to patients with or without gallstones. The description of the luminal folds within the duct as valves or spiral valves is inaccurate and incomplete as other configurations were seen just as commonly as the spiral one.

ACKNOWLEDGMENTS

We are grateful to the Swann-Morton Foundation (Sheffield, UK) for financial support to RCO during this study and to the Departments of Sports Engineering and Mechanical Engineering (University of Sheffield) for providing facilities for the scanning and computer reconstructions. We would also like to thank Mrs. S.E. Higham for the preparation of the resin casts.

REFERENCES

- Ahmed R, Bird NC, Chess-Williams R, Thomas WEG, Johnson AG. 2000. In vitro responses of gallbladder muscle from patients with acalculous biliary pain. *Digestion* 61:140–144.
- Bird NC, Ahmed R, Chess-Williams R, Johnson AG. 2002. Active relaxation of human gallbladder muscle is mediated by ATP-sensitive potassium channels. *Digestion* 65:220–226.
- Caroli-Bosc FX, Demarquay JF, Conio M, Deveau C, Hastier P, Harris A, Dumas R, Delmont JP. 1997. Is biliary lithogenesis affected by length and implantation of cystic duct? *Dig Dis Sci* 42:2045–2051.
- Castelain M, Grimaldi C, Harris AG, Caroli-Bosc FX, Hastier P, Dumas R, Delmont JP. 1993. Relationship between cystic duct diameter and the presence of cholelithiasis. *Dig Dis Sci* 38:2220–2224.
- Courtney DF, Clanachan AS, Scott GW. 1983. Cholecystokinin constricts the canine cystic duct. *Gastroenterology* 85:1154–1159.
- Deenitchin GP, Yoshida J, Chijiwa K, Tanaka M. 1998. Complex cystic duct is associated with cholelithiasis. *HPB Surg* 11:33–37.
- Dodds WJ, Hogan WJ, Geenen JE. 1989. Motility of the biliary system. In: Schultz SG, editor. *Handbook of physiology: the gastrointestinal system*. Vol. 1, section 6, part 2 (28). Bethesda, Maryland: American Physiological Society. p 1055–1101.
- Gray H, Lewis WH. 1918. *Anatomy of the human body*. Philadelphia: Lea and Febiger.
- Heister L. 1732. *Compendium anatomicum totum rem anatomicam*. Vols. 1, 2. Nurnberg: GC Weber. p 190.
- Ianora AAS, Memeo M, Scardapane A, Rotondo A, Angelelli G. 2003. Oral contrast-enhanced three-dimensional helical-CT cholangiography: clinical applications. *Eur Radiol* 13:867–873.
- Ichii H, Takada M, Kashiwagi R, Sakane M, Tabata F, Ku Y, Fujimori T, Kuroda Y. 2002. Three-dimensional reconstruction of biliary tract using spiral computed tomography for laparoscopic cholecystectomy. *World J Surg* 26:608–611.
- Jacobson C, Gydesen C. 1922. The function of the gallbladder in biliary flow. *Arch Surg* 5:374–394.
- Keith A. 1903. The nature and anatomy of enteroptosis (Glénard's disease). *Lancet* 1:631–640.
- Lichtenstein ME, Ivy AC. 1937. The function of the "valves" of Heister. *Surgery* 1:38–53.
- Mentzer SH. 1926. The valves of Heister. *Arch Surg* 13:511–522.
- Ooi RC, Luo XY, Chin SB, Johnson AG, Bird NC. 2004. The flow of bile in the human cystic duct. *J Biomech* 37:1913–1922.
- Otto WJ, Scott GW, Rodkiewicz CM. 1979. A comparison of resistances to flow through the cystic duct and the sphincter of Oddi. *J Surg Res* 27:68–72.
- Pitt HA, Roslyn JJ, Kuchenbecker SL, Doty JE, DenBesten L. 1981. The role of cystic duct resistance in the pathogenesis of cholesterol gallstones. *J Surg Res* 30:508–514.
- Scott GW, Otto WJ. 1979. Resistance and sphincter-like properties of the cystic duct. *Surg Gynecol Obstet* 149:177–182.
- Steiner D, Henning R, Lierse W. 1989. Bioconstruction of the extrahepatic biliary duct system in minipigs. *Acta Anat* 136:159–164.
- Torsoli A, Ramorino ML, Alessandrini A. 1970. Motility of the biliary tract. *Rendic R Gastroenterol* 2:67.
- Wegstapel H, Bird NC, Chess-Williams R, Johnson AG. 1999. The relationship between in vivo emptying of the gallbladder, biliary pain, and in vitro contractility of the gallbladder in patients with gallstones: Is biliary colic muscular in origin? *Scand J Gastroenterol* 34:421–425.